

Contact Lens Update

CLINICAL INSIGHTS BASED IN CURRENT RESEARCH

Everything you wanted to know and were afraid to ask about *Demodex*

December 7, 2015



Etty Bitton, OD, MSc is an Associate Professor and Director of the Université de Montréal's dry eye clinic.

It is almost impossible to pick up a clinical journal or go to a conference, lately, without stumbling upon the topic of *Demodex*. Although the significance of this parasite for humans was described as early as the 1960s,¹⁻³ its clinical relevance attracted limited attention. The incorporation of both diagnostic and therapeutic information has catapulted this organism to be the buzzword of the day in the realm of ocular surface health. Most clinicians vaguely remember, if at all, a brief description of *Demodex* in their ocular health course on lid disease. Little was known about the organism, except that it was often described as 'found universally' in older adults.⁴ However, its association with other ocular anomalies were unknown so consequently it fell off the differential diagnosis radar as a potential cause of anterior segment afflictions. This editorial offers an overview of the current knowledge on *Demodex* and its relevance to clinical practice.

What is *Demodex*?

Although several species of *Demodex* exist, only two inhabit humans, namely *Demodex folliculorum* and *Demodex brevis*.^{2, 5-12} This ectoparasite (living outside the human body) is the most common organism found on the human body and its presence increases with age. *D. folliculorum*, the larger of the two species (0.3-0.4mm), has an affinity for hair follicles including eyelashes, eyebrows, nose and ear hair, scalp, chest hair, underarms, etc. and is typically found in groups of mites. Alternatively, the shorter species, *D. brevis* (0.2-0.3mm), has a preference for sebaceous glands, including those on the face and the meibomian glands and tends to live on its own. The word *Demodex* originates from the Greek word 'demos' meaning 'fat' and 'dex' meaning 'worm'.²

The life cycle of *Demodex* varies between 14 to 18 days, going through different stages starting with the egg to larval stage to adult mite.¹¹⁻¹³ The adult mite has four bud-type legs on either side of its head, and has a head to body ratio¹¹ of 1:2 for the *D. folliculorum* and a 1:1 for *D. brevis*.

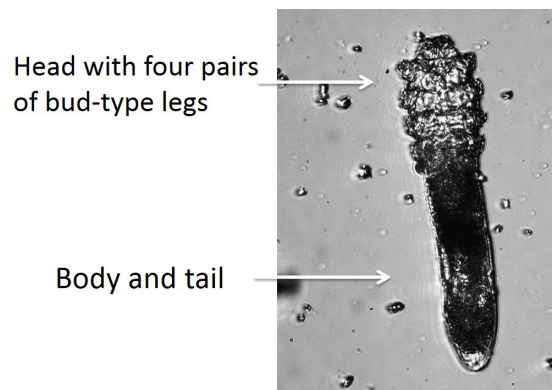


Figure 1: Microscopic view of *Demodex*

Female mites can lay as many as 10-12 eggs at a time, consequently leading to overpopulation of the infected area if left unmanaged. Prevalence of *Demodex* infestation increases with age, with a reported 84% in people >60 and 100% of patients >70 years of age.^{1,10} Direct contact is needed to transfer mites from one person to another, most probably through common household items such as linen, towels and toiletries.^{10,14} Contact lens wearers,¹⁵ those afflicted with acne rosacea,¹⁶⁻¹⁹ immuno-compromised patients,²⁰⁻²³ patients with blepharitis²⁴⁻²⁶ or history of chalazia²⁷⁻²⁹ have been reported to harbour greater numbers of *Demodex*.

The existence of the mite outside the human body is limited, although the exact timing is unknown.¹¹ The *Demodex* mite avoids light and buries itself head first in the follicles or glands, with only the tail visible at the opening of the lash follicle.^{2,10} The *D. folliculorum* mite burrows down the eyelash follicle to lay its eggs and ingests the gland lining using its sharp mouth, resulting in follicular distension and trichiasis (misdirected lashes). Debris generated from the mites accumulates at the root of the lashes and is clinically observed as a gelatinous cylindrical 'sleeve' or cylindrical dandruff (CD) at the base of the eyelash, which are pathognomonic for mite infestation.³⁰

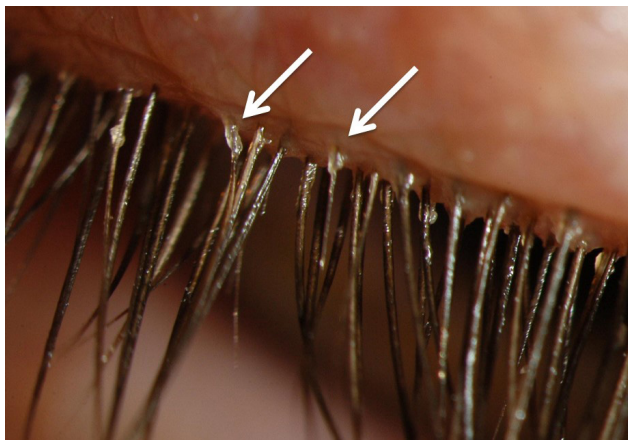


Figure 2: Cylindrical dandruff

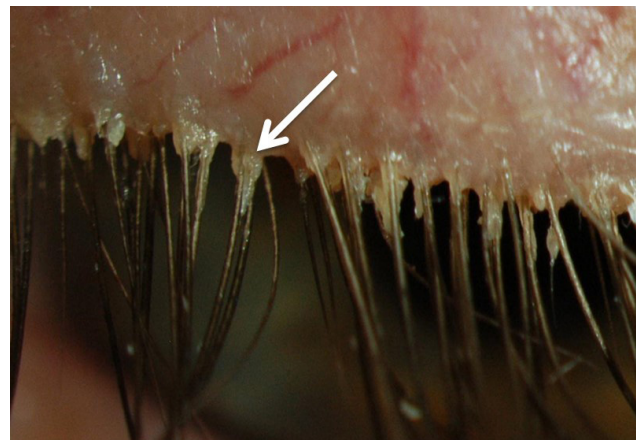


Figure 3: Distension of the follicle at the base of the eye last can be observed as a triangle shape.

This debris can be differentiated from other debris on the lashes, caused by make-up and other causative factors of anterior blepharitis (e.g. *Staphylococcus aureus*). One key indicator is that the cylindrical dandruff remains at the root of the lashes and is independent of lash growth. Contrary to the flaky yellow "collarettes" typical of blepharitis secondary to *Staphylococcus aureus* infection, which are found at any point on the lash as it elongates, the cylindrical dandruff associated with *Demodex* remains at the base of the lash.

Demodex mites have also been reported to act as vectors for bacteria (*staphylococci* and *streptococci*), either by carrying them on their body or within their gut (*bacillus oleronius*). Either way, the mite, its waste and cytoskeleton may all be contributory factors in generating an inflammatory or even an immune response on the ocular surface.^{11,19,27,31}

Clinical evaluation of *Demodex folliculorum*

Symptoms of *Demodex* infestation include ocular discomfort, itchiness, burning, foreign body sensation, blurry vision and dryness.^{10,32} One of the key symptoms in ocular demodicosis is itching,³³ especially along the lid margin. To date, there is no convincing evidence which correlates the minimum number of mites required to induce symptoms.^{11,34} Some *Demodex*-positive patients may even be asymptomatic,⁹ further confounding the true prevalence of *Demodex*, as these patients are less likely to present for examination.

Ocular signs include the pathognomonic cylindrical dandruff at the base of the lashes, trichiasis (misdirected lashes), madarosis (loss of lashes), telangiectasia and ocular hyperemia. Strong evidence of comorbidities has been reported, including meibomian gland dysfunction,²⁴⁻²⁶ recurrent chalazia²⁷⁻²⁹ and acne rosacea.^{16-19, 31}

To date, confirmation of diagnosis involves epilation of several sample lashes with cylindrical dandruff, which are then transferred to a microscopic slide so that the lashes and mites can be observed ex-vivo under a light microscope.¹⁰⁻¹¹




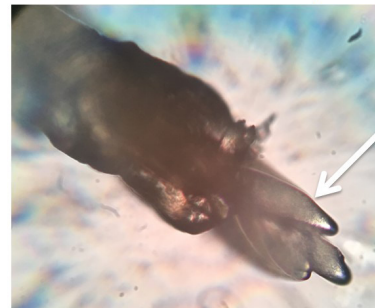
Figure 4: Five mites seen along the root of the lash

Low magnification (10X)



1 mite

High magnification (40X)



3-4 tails

Figure 5: Image on the left seems to only one mite, but a closer look (right) reveals several mites on the same eyelash, including at least 3-4 tails.

Confocal microscopy remains the only technique, to date, to view the mites in vivo, but this technology is likely to be restricted to an academic or research setting. Supplementary clinical observations have been proposed, including pinching the affected lash with tweezers and rotating it while observing, under high slit lamp magnification, the tails of the mite emerge from the follicle.³⁶ Emerging technologies that are helpful in viewing *Demodex* include the BlephCam (Scope Ophthalmics, UK),³⁷ a portable illuminated digital camera that magnifies the lid margin to enhance observation. The BlephCam offers an alternative to view the lid margin and educate patients if anterior segment imaging is not available.

A proposed severity scale for ocular *Demodex* infestation, or demodicosis, is dependent on the number of lashes with cylindrical dandruff.³⁸ Severity can be divided into mild (<5 lashes with cylindrical dandruff), moderate (5-9

lashes with cylindrical dandruff) and severe (>10 lashes have cylindrical dandruff); however, this scale is not yet widely utilized.

Management of *Demodex* infestation

The emphasis of therapy hinges on reducing the numbers of mites and alleviating symptoms such as itching. As with any therapy, patient education is key, to explain the nature of the problem and the life cycle of the parasite so that compliance is maintained for the prescribed period of time. Effective treatments against Demodex include pilocarpine gel,³⁹ oral ivermectin for ocular and skin demodicosis⁴⁰⁻⁴¹ and tea tree oil.⁴²⁻⁴⁵ Tea tree oil is derived from the leaves of *Melaleuca alternifolia*, a tree native to Australia, which possesses anti-microbial properties.⁴² In its pure form, it is extremely harsh to the skin, hence patient education is crucial in avoiding severe ocular irritation. Consequently, commercial formulations contain diluted tea tree oil, although the degree of dilution is not always divulged. Tea tree oil has been found to be toxic to the mites and assist in reducing mite counts by promoting their migration out of the follicles. They can then be removed by lid scrubs.⁴³⁻⁴⁵

Further research into tea tree oil has indicated that the active ingredient that Demodex is most sensitive to is terpinen-4-ol (T4O).⁴⁶ The only commercially available lid scrub with T4O is Cliradex® (Biotissue, USA), which remains the treatment of choice for many sufferers.¹¹ The recommended regimen involves cleaning along the lash line twice a day (bid) for three weeks, followed by a nightly treatment for another three weeks, to coincide with the lifecycle of the mite and the eggs that will subsequently hatch. It is recommended that clinicians demonstrate the use of Cliradex® with patients, as it is associated with a cooling/burning sensation similar to that produced by menthol. Other lid scrubs intended for at home use and containing varying amounts of diluted tea tree oil formulations include: SteriLid (Theartears/Akorn),⁴⁸ Ocusoft Lid Scrub PLUS (Ocusoft),⁴⁹ I-lid'n Lash PLUS (I-med pharma)⁵⁰ and BlephaDex (Macular Health),⁵¹ but studies on these products have yet to be published.

Products designed for in-office use have also emerged, such as I-lid'n Lash PRO (I-med pharma),⁵⁰ with 20% tea tree oil, and Oust™ Demodex® Swabstix™ (Ocusoft),⁵² with a combination of tea tree oil, sea buckthorn and coconut oil, however their efficacy have not yet been reported in the literature. Patient instruction is key in using these products, as the increased tea tree oil concentration is harsher to the skin and ocular surface and may necessitate topical anesthesia prior to use. Mechanical cleaning along the lash line using a novel instrument, BlephEx (Rysurg),⁵³ has also been shown to alleviate symptoms of anterior blepharitis and dislodge debris via a rotating disposable medical sponge tip.

Patients can also contribute to limiting re-infestation by changing linen and towels more often, discarding eye makeup such as mascara, using tea tree oil-based shampoo for their hair and having close family members checked.

Demodex infestation has been shown to affect ocular comfort,^{10,32} play a role in skin (acne rosacea) and ocular (blepharitis, chalazia) afflictions⁹ and potentially lead to discontinuation of contact lens wear.¹⁴ These should all be strong motivators for clinicians to take a proactive role in identifying *Demodex* and advocating for a healthy lid margin.

REFERENCES

1. Post CF, Juhlin E. Demodex folliculorum blepharitis. *Arch Dermatol* 1963;88: 298-302.
2. Coston TO. Demodex folliculorum blepharitis. *Trans Am Ophthalmol Soc* 1967;65: 361-92
3. Akbulatova LK. The pathogenic role of Demodex mite and the clinical form of demodicosis in man. *Vestnik Dermatologii i venerologii* 1963;40: 57-61
4. Catania LJ. *Demodicosis*. In ed. Primary Care of the Anterior Segment, 2nd edition. 1995; Appleton & Lange; Norwalk, Connecticut.
5. Edmondson II W, Christenson MT. Lid *Parasites*. In: Clinical Optometric Pharmacology and Therapeutics (Onefrey B, editor.,

- Lippincott-Raven, Philadelphia: 1992.
6. Lacey N, Kavanagh K, Tseng SC. Under the lash: Demodex mites in human diseases. *Biochem (Lond)*. 2009;31(4): 2-6.
 7. Nutting WB. Hair follicle mites (Acari: Demodicidae) of man. *Int J Dermatol* 1976;15(2): 79-98.
 8. English FP, Nuttin WB. Demodicosis of ophthalmic concern. *Am J Ophthalmol* 1981;91: 362-372.
 9. Liu J, Sheha H, Tseng SC. Pathogenic role of Demodex mites in blepharitis. *Curr Opin Allergy Clin Immunol* 2010 10(5): 505-10.
 10. Hom MM, Mastrotta KM, Schachter SE. *Demodex*. *Optom Vis Sci* 2013 90(7): e198-205.
 11. Cheng AMS, Sheba H, Tseng SCG. Recent advances on ocular Demodex infestation. *Curr Opin Ophthalmol* 2015;26: 295-300.
 12. Ruffi T, Mumcuoglu Y. The hair follicle mites Demodex folliculorum and Demodex brevis: Biology and medical importance. A review. *Dermatologica* 1981;162: 1–11.
 13. Rather PA, Hassan I. Human Demodex Mite: The versatile mite of dermatological importance. *Indian J Dermatol* 2014;59(1): 60–66.
 14. Tarkowski W, Moneta-Wielgos J, Mlocicki D. Demodex sp. As a potential cause of the abandonment of soft contact lenses by their existing users. *Biomed Res Int* 2015 Epub ahead of print (<http://www.ncbi.nlm.nih.gov/pubmed/26290865>).
 15. Jalbert I, Rejab S. Increased numbers of Demodex in contact lens wearers. *Optom Vis Sci* 2015;92(6): 671-8.
 16. Forton F, Seys B. Density of Demodex folliculorum in rosacea: a case control study using standardized skin-surface biopsy. *Br J Dermatol* 1993;128: 6509.
 17. Erbagci Z, Ozgostasi O. The significance of Demodex folliculorum density in rosacea. *Int J Dermatol* 1998;37: 421-5.
 18. Lacey N, Delaney S, Kavanagh K, et al. Mite-related bacterial antigens stimulate inflammatory cells in rosacea. *Br J Dermatol* 2007;157: 474-81.
 19. Li J, O'Reilly N, Sheba H et al. Correlation between serum immune-reactivity to Demodex-associated Bacillus proteins in patients with facial rosacea. *Ophthalmology* 2010;117: 870-7.
 20. Holmes RB, Martins C, Horm T. The histopathology of folliculitis in HIV-infected patients. *J Butan Pathol* 2002;29: 93-5.
 21. Aydingoz IE, Dervent B. Demodex folliculorum in renal transplant patients revisited. *Dermatology* 2001;203: 272-3.
 22. Erbagci Z, Erbacı I, Erkilic S. High incidence of demodicidosis in eyelid cell carcinomas. *Int J Dermatol* 2003;42: 567-71.
 23. Castanet J, Monpoux F, Mariani R et al. Demodicidosis in an immunodeficient child. *Pediatr Dermatol* 1997;14: 219-220.
 24. De Venecia AB, Siong RLB. Demodex sp. Infestation in anterior blepharitis, meibomian gland dysfunction, and mixed blepharitis. *Philippine J Ophthalmol* 2011;36: 15-22.
 25. Zhao YE, Wu LP, Xu JR. Association of blepharitis with Demodex: A meta-analysis. *Ophthalmic Epidemiology* 2012;19(2): 95-102.
 26. Bhandari V, Reddy JK. Blepharitis: Always remember Demodex. *Middle East Afr J Ophthalmol* 2014;21(4): 317-320.
 27. Liang L, Ding X, Tseng SC. High prevalence of Demodex brevis infestation in chalazia. *Am J Ophthalmol* 2014;157: 342-8.
 28. Schear MJ, Milman T, Steiner T, et al. The association of Demodex with chalazia: A histopathologic study of the eyelid. *Ophthalm Plast Reconstr Surg* 2015; Epub ahead of print (<http://www.ncbi.nlm.nih.gov/pubmed/26108058>).
 29. Tarkowski W, Owczynska M, Blaszczyk-Tyszka A, et al. Demodex mites as potential etiological factor in chalazion-a study in Poland. *Acta Parasitol* 2015;60(4)777-83 Epub ahead of print (<http://www.ncbi.nlm.nih.gov/pubmed/26408604>).
 30. Gao YY, Di Pascuale MA, Li W et al. High prevalence of Demodex in eyelashes with cylindrical dandruff. *Invest Ophthalmol Vis Sci* 2005;46: 3089-94.
 31. O'Reilly N, Menezes N, Kavanagh K. Positive correlation between serum immuno-reactivity to Demodex-associated Bacillus proteins and erythematotelangiectic rosacea. *Br J Dermatol* 2012;167: 1032-6.
 32. Lee SH, Chun YS, Kim JH, et al. The relationship between Demodex and ocular discomfort. *Invest Ophthalmol Vis Sci* 2010;51: 2906-11.
 33. Gao YY, Xu DL, Huang I J, Wang R, et al. Treatment of ocular itching associated with ocular demodicosis by 5% tea tree oil ointment. *Cornea* 2012;31(1): 14-7.
 34. Wesolowska M, Knysz B, Reich A, et al. Prevalence of Demodex spp, in eyelash follicles in different populations. *Arch Med Sci* 2014;10: 319-24.
 35. Randon M, LiangH, El HM et al. In vivo confocal microscopy as a novel and reliable tool for the diagnosis of Demodex eyelid infestation. *Br J Ophthalmol* 2015;99: 336-41.
 36. Mastrotta KM. Method to identify Demodex in the eyelash follicle without epilation. *Optom Vis Sci* 2013;90(6): e172-4.

37. Blephcam, Scope Ophthalmics. URL <http://www.blephexlids.co.uk/blephcam%E2%84%A2> (Accessed Oct 28, 2015)
38. Schachter S. A different approach to treating demodex blepharitis. *Optom Times*. 2014 Jan 3. URL <http://optometrytimes.modernmedicine.com/optometrytimes/content/tags/blephex/different-approach-treating-demodex-blepharitis>. (Accessed Oct 28, 2015).
39. Fulk GW, Murphy B, Robins MD. Pilocarpine gel for the treatment of demodicosis-A case series. *Optom Vis Sci* 1996;73: 742-5.
40. Salem DAB, El-Shazly A, Nabih N et al. Evaluation of the efficacy of oral ivermectin in comparison with ivermectin-metronidazole combined therapy in the treatment of ocular and skin lesions of Demodex folliculorum. *Int J Infectious Diseases* 2013;17: e343-7.
41. Holzchuh FG, Hida RY, Moscovici BK, et al. Clinical treatment of ocular demodex folliculorum by systemic ivermectin. *Am J Ophthalmol* 2011;151: 1030-4.
42. Carson CF, Hammer KA, Riley TV. Melaleuca alternifolia (Tea Tree) oil: a review of antimicrobial and other medicinal properties. *Clin Microbiol Rev* 2006;19(1): 50-62.
43. Gao YY, Di Pascuale MA, Li W, et al. In vitro and in vivo killing of ocular Demodex by tea tree oil. *Br J Ophthalmol* 2005;89(11): 1468-73.
44. Gao YY, Di Pascuale MA, Elizondo A, et al. Clinical treatment of ocular demodocosis by lid scrub with tea tree oil. *Cornea*. 2007;26(2): 136-43.
45. Koo H, Kim TH, Kim KW et al. Ocular surface discomfort and Demodex: effect of tea tree oil eyelid scrub in Demodex blepharitis. *K J Med Sci* 2012;27:1574-9.
46. Tighe S, Gao YY, Tseng SCG. Terpinen-4-ol is the most active ingredient of tea tree oil to kill demodex mites. *Translational Vis Sci Tech* 2013;2: 1-8.
47. Cliradex. URL <http://www.cliradex.com/> (Accessed Oct 28, 2015)
48. Sterilid (Theralid in Canada). URL <http://www.theratears.com/sterilid/> (Accessed Oct 28, 2015).
49. Ocusoft Lid scrub PLUS. Ocusoft. URL <http://www.ocusoft.com/ocusoft-lid-scrub-plus-pre-moistened-pads-30ctn> (Accessed Oct 28, 2015).
50. I-lid'n Lash PLUS/PRO. I-MED Pharma Inc. URL <http://imedpharma.com/ocular-hygiene> (Accessed Oct 28, 2015).
51. BlephaDex. Macular Health. URL <https://www.macularhealth.com/product/blephadex-eyelid-wipes>. (Accessed Oct 28, 2015).
52. Oust Demodex Swabstix (Ocusoft) URL <http://ocusoft.com/oust-demodex-swabstix-12box> (Accessed Oct 28, 2015).
53. BlephEx. RySurg, LLC. URL <http://www.rysurg.com> (Accessed Oct 28, 2015).