


Contact Lens Update

CLINICAL INSIGHTS BASED IN CURRENT RESEARCH

Managing Demodex in clinical practice

December 7, 2015



Sarah Farrant is a practicing UK optometrist. She has a special interest in dry eye and therapeutics and was one of the first optometrists to set up a dedicated dry eye clinic in her practice.

Affecting 100% of patients over the age of 70 and up to 20% of those under the age of 20, *Demodex* mites can be a nuisance for susceptible individuals, and are emerging as a significant cause of blepharitis.



Figure 1: *Demodex folliculorum* under the microscope (image courtesy of David Crystal)

Once I became aware of *Demodex* as a significant cause of blepharitis, it was quite straightforward to include looking for *Demodex* infestation as an integral part of my dry eye examination. My treatment has evolved with the advent of new ideas and strategies based on the research available. Once diagnosed, and after initial management, my patients who exhibit *Demodex* typically receive regular treatment every six months. The wonderful thing about treating *Demodex* blepharitis properly is that patients' symptoms really do improve significantly, and for that they are always very grateful!

DIAGNOSING DEMODEX

Demodex mites can only be viewed under high magnification (40x or higher), but other signs and symptoms may alert you to their presence.

Symptoms of *Demodex* and other forms of blepharitis are similar, including dry, itchy eyes and lids.

You may suspect that your patient has *Demodex* at the root of their issues if typical hygiene and/or blepharitis treatments have not been effective. Tea tree oil is mitacidal, and the only treatment that has been proven to kill *Demodex* mites.¹

Symptoms of *Demodex* include dry eye and itchiness. These symptoms may stem from a reaction to the debris and waste generated by the mites. Inflammation may also result from the bacteria present on the mites. Symptoms tend to be worse at night and upon waking. *Demodex* blepharitis classically has minimal inflammation or redness.

Patients with *Demodex* often present with other skin conditions. Consider *Demodex* in patients with signs of, rosacea,² chronic inflammatory dermatosis (mid-face) and even recurrent chalazia,³ although the role of *Demodex* in meibomian gland dysfunction has not been fully established.

***Demodex* hide in cylindrical sleeves of dandruff made up of lipids, decomposed mites and keratins (skin proteins), located around the base of the eyelash follicles (Figures 2-4).**^{1,4} The presence of these cylindrical collarettes are pathognomonic for *Demodex*.¹ Their tails become visible through a slit lamp examination (at 40x magnification or higher) once these dandruff crusts are removed (Figures 5 and 6).

TREATING AND MANAGING DEMODEX

I used the published evidence to develop the following strategies for my patients with clinically significant and/or symptomatic *Demodex* blepharitis:

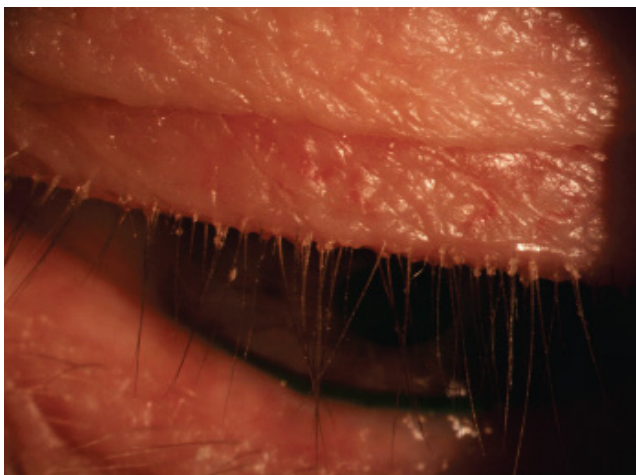


Figure 2: The cylindrical dandruff associated with *Demodex* can be seen at the base of the lenses with no magnification.

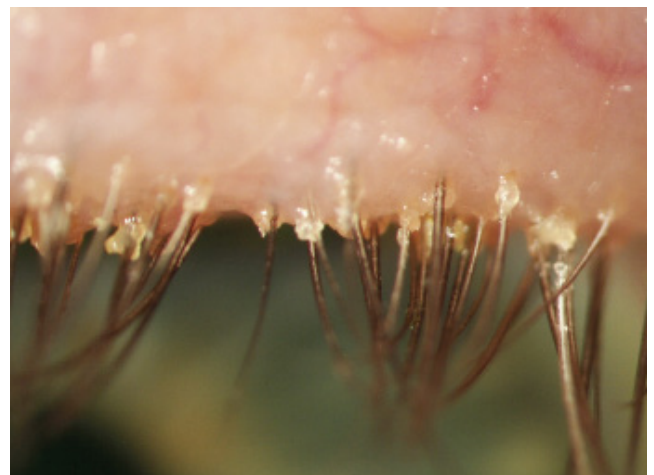

Figure 3: With higher magnification, the waxy appearance of the cylindrical dandruff becomes more apparent.



Figure 4: The cylindrical dandruff can be removed easily with a fine forceps.

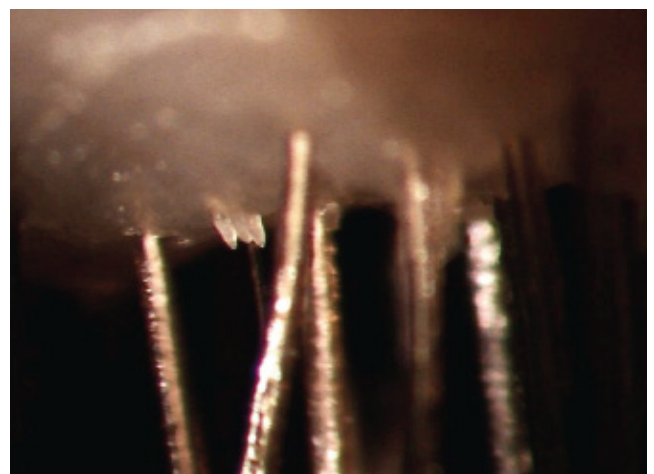


Figure 5: With dandruff removed, the mites' tails are visible.



Figure 6: The mites can be removed and viewed with a fine forceps (at 40x magnification or higher).

General advice for patients: Prevention and control of *Demodex*

- Wash body and hair and face with tea tree oil shampoo or shower gel.¹
- Wash bed sheets and towels in hot water. Ideally, they should be washed at a minimum temperature of 55°C (130°F), to kill bacteria and other microorganisms;^{5,6} however, some safety guidelines encourage consumers to set domestic hot water heaters to only 49°C (120°F) to avoid scalding.⁶

In-office procedures:

Explain the following procedures to the patient carefully. Obtain consent before proceeding with treatment. If you plan to mix tea tree oil with macadamia nut oil, as outlined below, ensure that the patient does not have a nut allergy:

1. Apply a topical anaesthetic to the lid margins and ocular surface.
2. Remove eyelash collarettes and crust from all four lids to expose the mite tails in preparation for the application of tea tree oil (Figure 7). I use Blephex®, an instrument that easily and quickly removes crusts and collarettes from the lashes. This procedure is performed with the eyes closed and takes about three to five minutes per eye. Removal of the debris is also generally a hygiene treatment for any type of blepharitis. I liken this procedure to deep cleaning a patients' teeth at the dentist!
3. Use a cotton bud to carefully apply a 50% tea tree oil solution to the closed eyelids (Figure 8). I mix the tea tree oil with 50% macadamia nut oil (as per recommendation⁷) directly to the outer lids and in amongst the lashes.
4. Tea tree oil, even diluted, can produce an intense sensation. Instruct the patient to keep their eyes closed and wait for the sensation to pass.

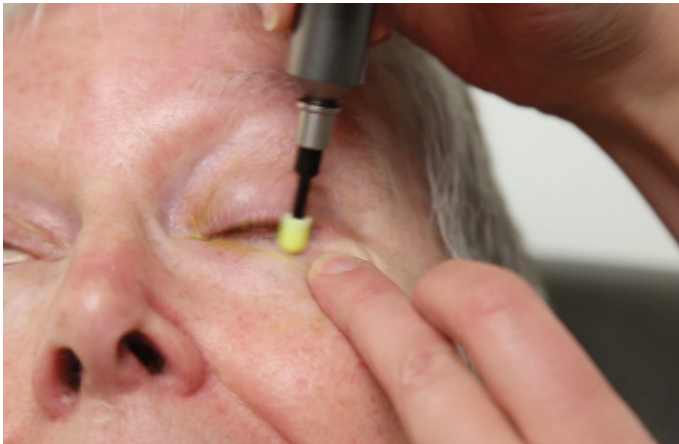

Figure 7: Use a clinical tool such as BlephEx to remove dandruff.

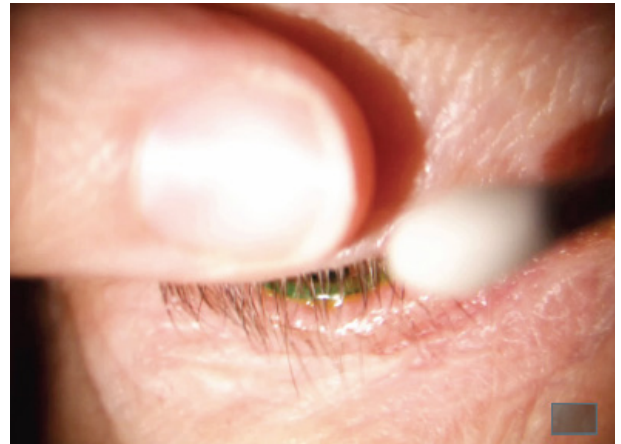

Figure 8: Use a cotton bud to apply tea tree oil solution to the lashes and lids.

Re-treat weekly for four weeks, to kill mites emerging from the eggs. Review in four to six months, with a view to repeating the procedure on an ongoing basis at approximately this interval.

At home patient procedures:

Provide patients with the following instructions for home hygiene:

- Clean lids once a day with a tea tree oil-based product. Depending on your location, your patients may have access to tea tree oil-based facial wipes or antiseptic cream; if they do not, they can dilute tea tree oil shampoo in water. They should continue this regimen for roughly six weeks (approximately two life cycles). Sensitive patients may develop dermatitis with exposure to tea tree oil.
- Continue standard lid hygiene, e.g. Blephasol Ocusoft or Sterilid.
- Advise the patient to return if their symptoms flare up again before their next scheduled visit.

Final thoughts:

Although this treatment is highly effective in the short term, be aware that your patients may need to return every few months for follow-up treatment, as the mites are likely to return. The following images demonstrate this cycle, with Figure 9 showing lids pre-treatment, Figure 10 showing lids immediately after treatment and Figure 11 showing lids a few months after treatment.

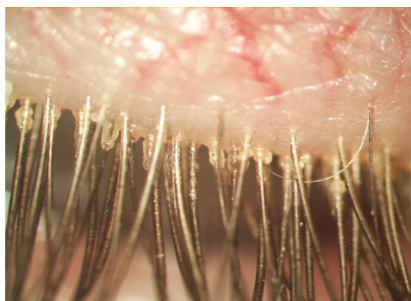

Figure 9: Pre-treatment

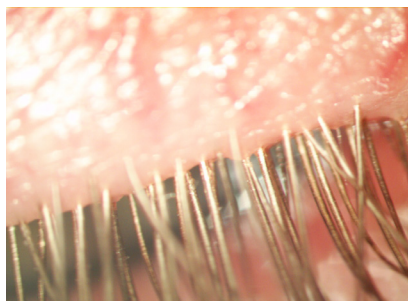


Figure 10: Immediately post-treatment

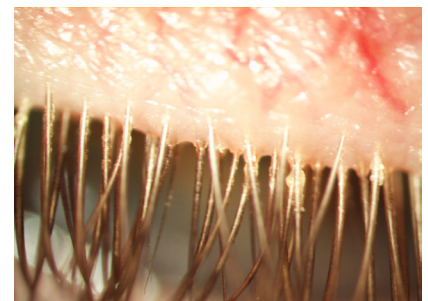


Figure 11: Three months post-treatment

REFERENCES

1. Gao YY, Di Pascuale MA, Li W, et al. In vitro and in vivo killing of ocular *Demodex* by tea tree oil. *Br J Ophthalmol*. 2005;89(11):1468-73.
2. Lacey N, Kavanagh K, Tseng SC. Under the lash: *Demodex* mites in human diseases. *Biochem* 2009;31(4): 2–6.
3. Liang L, Ding X, Tseng SC. High prevalence of *Demodex brevis* infestation in chalazia. *Am J Ophthalmol* 2014;157(2): 342–348.
4. Gao YY, Di Pascuale MA, Li W, et.al. High prevalence of *Demodex* in eyelashes with cylindrical dandruff. *Invest Ophthalmol Vis Sci* 2005;46(9): 3089-3094.
5. McDonald LG, Tovey Euan. The role of water temperatre and laundry procedures in reducing house dust mite populations and allergen content of bedding. *J Allergy Clin Immunol* 1992; 90(4): 599-608.
6. Levesque B, Lavoie M, Joly J. Residential water heater temperature: 49 or 60 degrees Celsius? *Can J Infect Dis* 2004;15(1): 11-12.
7. Schachter S. A different approach to treating *Demodex* blepharitis. *Optometry Times*, January 3, 2014.